Uncommon Oral Pathology- What Now?

Author: Amy M.K. French, DMD, MS

When an unusual case lands in our lap, what do we do? What steps do we take to ensure that we don't have our blinders on from our typical, day-to-day caseloads? How do we make certain that our patient receives the care they need?

The case below is that of a young woman who sought me out for a second opinion. She had been told by another periodontist that she would need to have multiple extractions, and she was desperate to determine if there were any alternatives. The pre-treatment panoramic radiograph demonstrates several features, some of which could be confounding or confusing and which could tend to lead us down a pre-determined diagnostic path. We see generalized moderate to severe horizontal bone loss in the maxilla (confirmed by a separate set of intraoral periapical radiographs). In the mandible, we can visualize two distinct radiolucencies surrounding the roots of #19/20 and #29/30. If we diagnosed based upon our "first glance," we could potentially assume that this patient has severe periodontal disease, perhaps a couple of periodontal-endodontic lesions.



If we look closer, we might question the initial diagnosis, ***remembering that although we shouldn't necessarily go looking for zebras where there are horses, sometimes a zebra might actually be present.*** In this case, those features are evidence of root resorption on #19, the bilateral location and *relative symmetry* of the mandibular lesions. Clinical charting and other diagnostic tests were undertaken in addition with consultations with other colleagues. This led to the formulation of clinical differential diagnoses including Langerhan's cell histiocytosis and central giant cell granuloma (CGCG) among others. Given the amount of bony destruction present in both arches, the lack of comorbidities such as uncontrolled diabetes, and the absence of local factors such as heavy plaque and calculus, bloodwork was also requested to include CBC and

Amy M.K. French, DMD, MS
Corneliu Sima, DMD, MSc, DSc
James K Burnham, DDS, MS
6148 Mae Anne Avenue, #1
Reno, NV 89523
(775) 322-5122
frontdesk@sierranvperio.com

vitamin D levels. Incisional biopsy of both sites was recommended to the patient in order to guide further decision making. The patient was definitively diagnosed with CGCG at the #29/30 site, chronic periodontitis at the #19/20 site. Bloodwork also demonstrated a signficant vitamin D deficiency. The patient decided upon definitive treatment for the CGCG at #29/30 first, which unfortunately involved extraction of those teeth. She also began vitamin D supplementation. Given the amount of bony destruction at #19/20, extraction of those teeth was also recommended. However, before beginning definitive peridontal treatment of the maxillary arch and the mandibular left, the patient returned for generalized re-assessment of her condition. New radiographs were obtained; again the findings were striking. At #19/20, we can see near complete resolution of the radiolucent lesion- the only change had been the vitamin D supplementation.

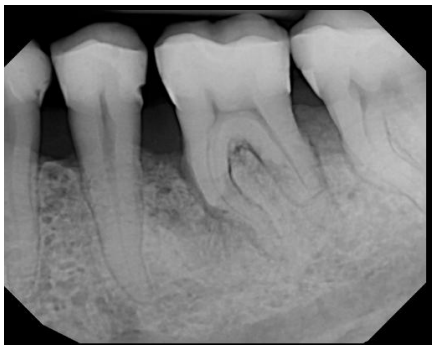

Given the bony regeneration of that site, extractions were now off the table. The patient then pursued definitive periodontal therapy of the maxillary arch (LANAP®), which thankfully also responded beautifully.

Beyond being a feel-good story with some great radiographs, what does this case remind us to do? It reminds us to *maintain our awareness to keep our diagnositic skills sharp*. Biopsy is always an option for our patients if we are uncertain of the diagnosis. We should never shy away from recommending it if it will help us obtain the correct diagnosis and therefore provide the correct treatment plan.

Amy M.K. French, DMD, MS
Corneliu Sima, DMD, MSc, DSc
James K Burnham, DDS, MS

6148 Mae Anne Avenue, #1
Reno, NV 89523

(775) 322-5122
frontdesk@sierranvperio.com